

Case Report

Refractory Hypotension post Coronary Artery Bypass Graft Unmasking Hypoaldosteronism: Case Report and Literature Review

Carla Sawan¹, Nadine Kawkabani^{2,*}, Youmna Francis¹, Omar Boustros³, Simon Bejjani³, Fadi Abou Jaoudeh⁴, Rola Darwiche², Bassam Abou Khalil³

¹Department of Endocrinology, Saint George Hospital University Medical Center, University of Balamand, Beirut, Lebanon

²Department of Cardiac Anesthesia, Saint George Hospital University Medical Center, University of Balamand, Beirut, Lebanon

³Department of Cardiothoracic Surgery, Saint George Hospital University Medical Center, University of Balamand, Beirut, Lebanon

⁴Department of Cardiology, Saint George Hospital University Medical Center, University of Balamand, Beirut, Lebanon

Email address:

nadine_kaoukabani@yahoo.com (N. Kawkabani)

*Corresponding author

To cite this article:

Carla Sawan, Nadine Kawkabani, Youmna Francis, Omar Boustros, Simon Bejjani, Fadi Abou Jaoudeh, Rola Darwiche, Bassam Abou Khalil. Refractory Hypotension post Coronary Artery Bypass Graft Unmasking Hypoaldosteronism: Case Report and Literature Review. *International Journal of Cardiovascular and Thoracic Surgery*. Vol. 5, No. 2, 2019, pp. 47-50. doi: 10.11648/j.ijcts.20190502.14

Received: March 27, 2019; Accepted: May 17, 2019; Published: June 12, 2019

Abstract: The sympathetic nervous system and the renin-angiotensin-aldosterone system (RAAS) are the cornerstones of cardiovascular adaptation. The simultaneous presence of disorders involving both is not uncommon, especially in patients with coronary artery disease undergoing coronary artery bypass surgery (CABG). This is the case of a patient with both hyporeninemic hypoaldosteronism and autonomic dysfunction. This article describes his clinical course before and after CABG surgery, along with a literature review of those interrelated entities. Our patient is a 63-year-old male with a history of hypertension and hyperlipidemia presenting for CABG for triple vessel disease. On the day of admission, the patient had sudden unprovoked loss of consciousness along with hypotension and bradycardia. He reported having had similar episodes in the past at times of emotional stress. After stabilization, the patient underwent CABG surgery the next day and it was uneventful. Four hours later, he developed another episode of hypotension with bradycardia which resolved upon administration of fluids. On postoperative day 2, while removing the jugular line, he had loss of consciousness with 5 seconds pause recorded on his bedside monitor. A carotid massage confirmed carotid sinus hypersensitivity, which necessitated the insertion of a pacemaker. However, patient continued to have similar episodes despite a functioning device. Workup revealed hyporeninemic hypoaldosteronism with an undetectable aldosterone level, although patient was not diabetic, had normal cortisol level, and had no other risk factors for those findings. Patient was started on fludrocortisone 0.1 mg daily; his hemodynamics improved markedly, and his symptoms resolved permanently. Our patient has hyporeninemic hypoaldosteronism caused most likely by his autonomic dysfunction, rather than having of two separate entities. A review of the literature showed that primary autonomic insufficiency with reduced circulating norepinephrine levels prevent renin activation and subsequently aldosterone release, leading to hyporeninemic hypoaldosteronism. Coronary artery disease is a known cause of autonomic dysfunction and CABG surgery unmasks this entity, which explains the exacerbation of our patient's symptoms during this phase.

Keywords: RAAS, Hyporeninemic Hypoaldosteronism, CAD, CABG

1. Introduction

The sympathetic nervous system and the renin-angiotensin-aldosterone system (RAAS) are the cornerstones of cardiovascular adaptation. Normally, brisk changes from supine to standing position lead to pooling of blood at the periphery with subsequent activation of the RAAS and an increase in sympathetic resistance and heart rate with the aim of preventing orthostasis. Coronary artery disease is known to alter HRV (Heart Rate Variability), leading to symptoms of autonomic dysregulation such as orthostatic hypotension, arrhythmias, etc [1, 2].

Hyporeninemic hypoaldosteronism itself is part of a heterogeneous group of clinical disorders rarely genetic [3, 4] more often associated with mild to moderate renal insufficiency [5, 6], and with diabetic nephropathy, as a form of RTA (type IV) [7]. In rare instances, no intrinsic renal disease is found, as in the case we are describing, and another process is behind the deficiency in aldosterone.

In this article, we present the case of a patient with both hyporeninemic hypoaldosteronism and autonomic dysfunction, in the absence of underlying type 2 diabetes, impaired renal function or chronic use of beta blockers or NSAIDs. We describe the course of his hospital stay following CABG surgery including the management of frequent asystoles and hemodynamic instability.

2. Case Presentation

This is the case of a 63-year-old male patient known to have hypertension and hyperlipidemia admitted to our institution for coronary artery bypass grafting for triple vessel disease (LAD, OM1 and PDA).

His initial workup included a positive cardiac stress test followed by a cardiac catheterization that showed triple vessel disease necessitating surgery. Patient was taking Bisoprolol, Valsartan/Hydrochlorothiazide, Atorvastatin and Molsidomine.

There were no abnormal findings on physical exam upon admission, and all vitals were within normal range. However, 4 hours later, and while showering, the patient lost consciousness for about 10 seconds during which he was transiently hypotensive (60/30 mm Hg) and his heart rate was about 65 bpm. He received one liter of normal saline intravenously and he recovered immediately. His ECG at the time showed no significant changes compared to his baseline tracing.

Upon further investigation, the patient admitted to having had his first similar episode 15 years ago in addition to a few other similar episodes within the last year, consisting of syncopal episodes of vasovagal etiology, mostly during emotional stress. He underwent an ENT evaluation 2 weeks prior to this presentation for possible inner ear cause of his symptoms yet it was non-revealing.

On the second day of his hospitalization, the patient underwent an uneventful CABG operation for his triple vessels disease and was transferred to the cardiac surgical unit

for post-operative monitoring and management. Four hours later he developed another episode of unprovoked hypotension that resolved with the administration of neosynephrine.

For the following 24 hours, the patient's vital signs remained stable with a heart rate that ranged between 52 and 70 bpm, a systolic BP ranging between 98 and 164 mm of Hg, a cardiac index ranging between 2.7 L/min/m² and 3.5 L/min/m². The mixed venous O₂ remained above 70% throughout his course. His electrolytes panel and his hemoglobin/hematocrit levels were normal throughout his stay. His echocardiogram showed a normal ejection fraction and intact valvular function.

On the following day, the patient had 2 episodes of syncope associated with sweating, dizziness, and nausea followed by hypotension and loss of consciousness for around 10 seconds. There was no chest pain or shortness of breath during any of the episodes. Heart rate was stable around 60 bpm, without ischemic ECG changes. These 2 episodes occurred while the patient was lying in bed, without specific triggers. The ENT team ruled out one more time inner ear problem and the endocrinology team started the workup for adrenal insufficiency and ordered 8 AM ACTH, 8 AM cortisol, Renin and Aldosterone levels.

On postoperative day 2 and while removing the central line on the right side, the patient suddenly lost consciousness, and had a cardiac pause of 5 seconds recorded by his bedside monitor, along with a blood pressure of 70/45 mm Hg. He regained consciousness immediately afterwards with leg elevation.

The electrophysiology team was consulted and during their evaluation, a carotid massage was performed which resulted in a 7 seconds cardiac pause recorded on ECG. These consecutive events confirmed the presence of carotid sinus hypersensitivity. The decision was made to insert a pacemaker as a treatment for symptomatic carotid sinus syndrome secondary to symptomatic carotid sinus hypersensitivity manifested by recurrent syncopal episodes with life threatening cardiac pauses.

On postoperative day 4, the patient had another episode of syncope while trying to get out of bed. Blood pressure was 100/80 mm Hg with a heart rate of 66 bpm. The pacemaker was interrogated and was found to be functioning appropriately. The patient was well hydrated and maintained a good PO intake, yet his symptoms persisted. Neurological evaluation and workup including EEG, Brain CT and carotid Doppler, were all normal and nonrevealing. The endocrinology team was consulted in order to rule out adrenal hypofunction given persistent orthostasis and symptomatic hypotension. The results of the endocrinology workup showed an undetectable aldosterone level along with a low-normal renin level, findings suggestive of hyporeninemic hypoaldosteronism. There was no hyponatremia or hyperkalemia on the electrolytes panel. Of note that the patient is not known diabetic or to have renal insufficiency or to use ACEI/ARB or NSAIDs chronically, all being potential causes of hyporeninemic hypoaldosteronism. Serum cortisol and

ACTH levels were 19.13 microg/dl and 19.5 microg/dl, respectively. Aldosterone level was undetectable, and the renin level was 11 pg/mL (normal range is 2.5-45.7 pg/mL) (See Table 1). The patient was started on fludrocortisone 0.1 mg daily; his symptoms resolved completely, and his vital signs remained stable supine, standing and while ambulating.

During the following 2 days, patient’s heart rate remained between 63 and 74 bpm, and systolic blood pressure ranged

between 110 and 140 mm Hg. He was ambulating normally and reported resolution of his symptoms despite all positional changes.

One month later, and on outpatient follow up after discharge, the patient reported feeling much better, had a normal electrolyte panel, with complete resolution of his symptoms. (Table 1)

Table 1. Patient’s Data.

	Preop	D0	D1	D2	D3	D4	D5-D11	2 months later
BP in mm Hg	110/70 120/80	90/50 140/70	90/50 130/60	100/60 120/70	110/60 130/70	100/60 130/70	110/70 120/80	120/70
HR in bpm	60-70	55-70	60-70	70-80	70-85	70-80	70-80	70-80
Hct	38	26	30.7	28.8	27.6	29.3	29.5	35.4
Hb	13.6	8.5	10.1	9.6	8.9	9.5	9.6	11.7
Na+	142	148	141	140	143	141	140	146
K+	4.1	4.7	3.9	3.8	4.4	4.3	4.4	4.7
Cl-	95	103	105	106	105	102	106	108
Events				Pacemaker inserted		Fludrocortisone added	Aldosterone: Undetectable Renin: 11 pg/ml Cortisol: 19.13 microg/dl ACTH: 19.5 microg/dl	

3. Discussion and Literature Review

Our case is unique in the fact that it carries two diagnoses that converge in their clinical symptomatology. The patient was initially diagnosed with carotid sinus hypersensitivity, manifested by recurrent syncopal episodes and life threatening bradyarrhythmia upon pressuring the carotid body. After pacemaker placement, only the cardiac pauses resolved, leaving the patient with significant symptomatic hypotension, found to be caused by isolated hypoaldosteronism, as shown by the low normal renin, undetectable aldosterone level and normal cortisol level.

It is well established that Heart Rate Variability (HRV) is affected by coronary artery disease, namely following a myocardial infarction [1, 8]. Studies have also revealed a more pronounced reduction in HRV following cardiac and thoracic surgeries [2, 9], yet it was found to be temporary and reversible within 3-6 months from the operation.

There are two types of isolated hypoaldosteronism with normal glucocorticoid function, differentiated based on the renin level:

One form is isolated primary hyperreninemic hypoaldosteronism [10], which can be due to a zona glomerulosa defect, chronic idiopathic hypoaldosteronism, familial corticosterone methyl oxidase deficiency, persistent hypotension, prolonged heparin administration, as well as ACE-I therapy.

The second form is hyporeninemic hypoaldosteronism which occurs with prolonged type 2 diabetes [5, 11], tubulointerstitial nephritis, type IV renal tubular acidosis [3, 4], and chronic use of beta blockers and non-steroidal anti-inflammatory drugs. Hyponatremia and hyperkalemia generally occur in hypoaldosteronism. However, normokalemia with or without mild hyponatremia are not

unusual. Treatment with fludrocortisone in small doses is usually effective in restoring hemodynamic equilibrium.

This patient’s clinical picture and laboratory findings show hyporeninemic hypoaldosteronism associated with autonomic dysfunction. In the absence of underlying type 2 diabetes mellitus, impaired renal function [12], or chronic ACE-I or heparin use, the most likely cause of reduced aldosterone secretion in this case is the autonomic insufficiency itself. The chronic use of beta blockers might have unmasked the autonomic insufficiency rather than cause it. A review of the literature [6, 10-16] connects primary autonomic insufficiency to low renin levels. Normally, plasma norepinephrine released from postganglionic sympathetic terminals [13-15] stimulates renal prostacyclin release, which in turn activates renin from prorenin and promotes further renin release [7]. Another mechanism is one by which beta-adrenergic nerve terminals directly stimulate renin release from juxtaglomerular cells [6-16]. The reduced circulating norepinephrine levels occurring in autonomic insufficiency are the explanation for hyporeninemia through inadequate renin release or lack of conversion of prorenin to renin, and eventually the ensuing hypoaldosteronism. (Figure 1).

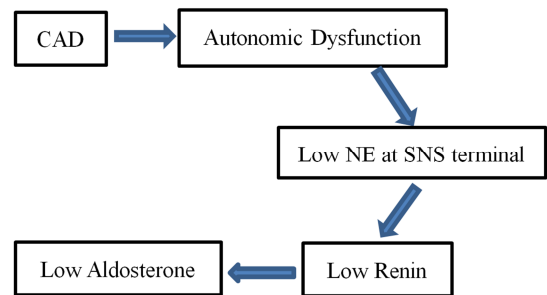


Figure 1. Schematic illustration of the pathway leading from autonomic dysfunction to hyporeninemic hypoaldosteronism.

In our case, the autonomic insufficiency is attributed to the underlying coronary artery disease [1, 2], and the CABG surgery has led to its worsening, as shown in the frequency of our patient's syncopal episodes and cardiac pauses postoperatively. The symptomatology of our patient was an overlap of two interconnected conditions, which explains partial improvement with the pacemaker placement to treat the autonomic dysfunction and complete resolution of his symptoms following fludrocortisone use.

4. Conclusion

Isolated Hyporeninemic Hypoaldosteronism as an entity has scarce literature describing it, notably in the last 5 years [10]. Autonomic dysfunction on the other hand is commonly seen among patients with coronary artery disease, with a notable exacerbation of symptoms in the setting of cardiac and thoracic surgeries. This case describes the coexistence of significant hyporeninemic hypoaldosteronism resulting from autonomic insufficiency, two phenomena that are interrelated rather than acting separately. The coronary artery disease is thought to be the cause of the autonomic dysfunction which in turn deactivates the RAAS, leading to isolated mineralocorticoid deficiency and low renin secretion. Our patient's autonomic insufficiency, as manifested by orthostasis and cardiac pauses, has worsened following the CABG surgery, necessitating placement of a pacemaker in order to prevent further life threatening bradyarrhythmias. The additional finding of hyporeninemic hypoaldosteronism is the reason behind the persistent hypotension. It is a consequence of the inadequate sympathetic function, necessitating fludrocortisone supplementation for hemodynamic stabilization.

References

- [1] Huikuri HV1, Stein PK. Heart rate variability in risk stratification of cardiac patients. *Prog Cardiovasc Dis.* 2013 Sep-Oct; 56 (2): 153-9.
- [2] Arnold AC, Ng J, Lei L, Raj SR. Autonomic Dysfunction in Cardiology: Pathophysiology, Investigation, and Management. *Can J Cardiol.* 2017; 33 (12): 1524–1534.
- [3] White PC. Aldosterone synthase deficiency and related disorders. *Mol Cell Endocrinol.* 2004 Mar 31; 217 (1-2): 81-7.
- [4] New MI, Lekarev O, Parsa A, et al. Genetic Steroid Disorders. In: Academic Press. 1st ed; 2013; Chapter 3D page 78
- [5] Sousa AG, Cabral JV, El-Feghaly WB, de Sousa LS, Nunes AB. Hyporeninemic hypoaldosteronism and diabetes mellitus: Pathophysiology assumptions, clinical aspects and implications for management. *World J Diabetes.* 2016; 7 (5): 101–111.
- [6] Szyłman P, Better OS, Chaimowitz C, et al. Role of hyperkalemia in the metabolic acidosis of isolated hypoaldosteronism. *N Engl J Med.* 1976; 294: 361-365.
- [7] DeLeiva A, Christlieb AR, Melby JC, et al. Big renin and biosynthetic defect of aldosterone in diabetes mellitus. *N Engl J Med.* 1976 Sep 16; 295 (12): 639-43.
- [8] Chen Y, Yu Y, Zou W, Zhang M, Wang Y, Gu Y. Association between cardiac autonomic nervous dysfunction and the severity of coronary lesions in patients with stable coronary artery disease. *J Int Med Res.* 2018; 46 (9): 3729–3740.
- [9] Lakusic N, Mahovic D, Kruzliak P, et al. Changes in Heart Rate Variability after Coronary Artery Bypass Grafting and Clinical Importance of These Findings. *Biomed Res Int.* 2015: 680515.
- [10] Wilczynski C, Shah L, Emanuele MA, Emanuele N, Mazhari A. Selective Hypoaldosteronism: A review. *Endocr Pract.* 2015 Aug; 21 (8): 957-65.
- [11] Tuck ML, Sambhi MP, Levin L. Hyporeninemic hypoaldosteronism in diabetes mellitus. Studies of the autonomic nervous system's control of renin release. *Diabetes.* 1979; 28: 237-241.
- [12] Data JL, Gerber JG, CrupWJ, et al. The prostaglandin system-A role in canine baroreceptor control of renin release. *Circ Res.* 1978 Apr; 42 (4): 454-8.
- [13] Ballermann BJ, Zeidel ML, Gunning ME, et al. Vasoactive peptides and the kidney. In: Brenner BM, Rector FC Jr (Eds). *The Kidney.* 4th ed. Philadelphia, Pa, WB Saunders; 1991; pp 515-17.
- [14] Polsky FI, Roque D, Hill PE. Hyporeninemic hypoaldosteronism complicating primary autonomic insufficiency. *West J Med.* 1993; 159 (2): 185–187.
- [15] Love DR, Brown JJ, Chinn RH, et al. Plasma renin in idiopathic orthostatic hypotension: Differential response in subjects with probable afferent and efferent autonomic failure. *Clin Sci.* 1971; 41: 289-99.
- [16] Rose BD, Post TW. *Clinical Physiology of Acid-Base and Electrolyte Disorders.* 5th ed. New York, NY: McGrawHill; 2001.