

Case Report

Atrial Septal Defect with Rheumatic Mitral Regurgitation: A Rare Association in a Nigerian Child

Olugbenga Olalekan Ojo^{1,*}, Uvie Ufuoma Onakpoya¹, John Akintunde Okeniyi², Anthony Taiwo Adenekan³, Muyiwa Afolabi Owojuyigbe³, Oluwakemi Tolu Adegoke⁴

¹Department of Surgery, College of Health Sciences, Obafemi Awolowo University, Obafemi Awolowo University Teaching Hospital, Ile-ife, Nigeria

²Department of Paediatrics and Child Health, Obafemi Awolowo University, Obafemi Awolowo University Teaching Hospital, Ile-ife, Nigeria

³Department of Anaesthesia and intensive care, College of Health Sciences, Obafemi Awolowo University, Obafemi Awolowo University Teaching Hospital, Ile-ife, Nigeria

⁴Department of Paediatrics and Child Health, Obafemi Awolowo University Teaching Hospital, Ile-ife, Nigeria

Email address:

gbengasbox@yahoo.co.uk (O. O. Ojo)

*Corresponding author

To cite this article:

Olugbenga Olalekan Ojo, Uvie Ufuoma Onakpoya, John Akintunde Okeniyi, Anthony Taiwo Adenekan, Muyiwa Afolabi Owojuyigbe, Oluwakemi Tolu Adegoke. Atrial Septal Defect with Rheumatic Mitral Regurgitation: A Rare Association in a Nigerian Child. *International Journal of Cardiovascular and Thoracic Surgery*. Vol. 5, No. 3, 2019, pp. 60-63. doi: 10.11648/j.ijcts.20190503.12

Received: August 12, 2019; **Accepted:** September 3, 2019; **Published:** September 18, 2019

Abstract: Atrial septal defect (ASD) coexisting with mitral valve regurgitation has been described in literature with various aetiologies and pathophysiologic mechanisms. Mitral valve lesions coexisting with an ASD could either be congenital or acquired. The most prominent congenital mitral valve pathology is a cleft in the anterior leaflet of the mitral valve, as seen in patients with partial atrio-ventricular septal defects. Acquired mitral valve lesions include, hemodynamic induced annular dilatation resulting in significant mitral regurgitation, iatrogenic leaflet perforation and coexisting diseases such as infective endocarditis or rheumatic valve disease. However, the aetiology of the mitral valve regurgitation being due to rheumatic heart disease is uncommon. We report the case of a 12-year-old female who presented with easy fatigability, palpitation and a precordial bulge dating about 2 years. Examination revealed cardiac murmurs in the apex and pulmonary areas and transthoracic echocardiography confirmed the presence of an Ostium Secundum ASD and features of severe rheumatic mitral valve regurgitation. Child was initially placed on medications which included diuretics and an Angiotensin converting enzyme inhibitor ACEi, before she eventually had surgical closure of ASD and mitral valve replacement. The purpose of this case report is to highlight the symptomatology, diagnosis and treatment of this rare association, particularly in our environment.

Keywords: Atrial Septal Defect, Ostium Secundum (OS), Rheumatic, Mitral Valve Regurgitation, Transthoracic Echocardiography

1. Introduction

Atrial septal defect (ASD) with rheumatic mitral stenosis is popularly known as Lutembacher syndrome; however the association of ASD and rheumatic mitral regurgitation has also been described, but remain unnamed. A recent report from India proposed that ASD with rheumatic mitral regurgitation should also be included in the definition of

Lutembacher syndrome [1].

Atrial septal defect (ASD) coexisting with mitral valve regurgitation has been described in literature with the incidence rate of 4 to 9.1% [2]. However, the rheumatic aetiology of the mitral regurgitation (MR) remains an important and distinct entity, which needs to be recognized in our environment.

2. Case Report

A 12-year-old girl presented at paediatric cardiology clinic with a two year history of easy fatigability and palpitations. Further questioning revealed poor weight gain, exercise intolerance and recurrent episodes of cough. There was no history of cyanosis or squatting. She and her grandmother (informant) could not recall any prior history of sore throat or joint pains.

Child is a product of unplanned teenage conception and her mother had made two attempts at medical abortion in the first trimester of pregnancy using over-the-counter drugs. Delivery, neonatal period, infancy and early childhood were adversely uneventful, with the child achieving all her developmental milestones at appropriate periods. On examination at presentation, she was underweight 26.0 kg, < 1st percentile, - 3.43 z, had a normal height 143 cm, 2nd percentile, - 1.92 z, was afebrile, not cyanosed with a pulse 96/minute regular, symmetrical and synchronous with other peripheral pulses. Jugular venous pressure (JVP) was elevated and she had a Precordial bulge with a hyperactive Precordium. Apex beat was at the 6th intercostal space, anterior axillary line with a left parasternal heave. Auscultation revealed fixed S2 splitting with a grade 4/6 pan-systolic murmur in the apex radiating to the axilla, and systolic flow murmur in the pulmonary area. The liver was palpably enlarged to 4 cm below the right costal margin and there was no ascites.

Her plain chest radiography (figure 1) showed cardiomegaly (cardiothoracic ratio of 0.77) with pulmonary plethora while electrocardiography showed right axis deviation and right ventricular hypertrophy. Blood investigations including Erythrocyte sedimentation rate (ESR:

10 mm/ hour) where all essentially normal.

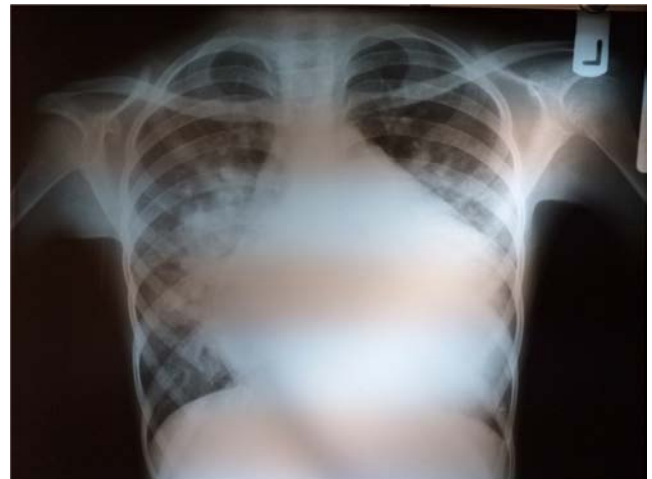

Figure 1. Chest X-ray showing cardiomegaly and pulmonary plethora.

Transthoracic echocardiography showed moderate pericardial effusion of 18.5 mm anteriorly, enlarged right heart chambers, a large OS ASD measuring 43.4 mm (figure 2), dilated main pulmonary artery (30.6 mm: + 2.87 z) and branches (Right PA = 21.8 mm; + 3.51 z and Left PA = 23.4 mm, + 4.69 z). There was severe mitral regurgitation (MR Area = 6.85 cm²) and moderate-severe tricuspid regurgitation (TR) with a maximal velocity of 3.45 m/ s. The posterior mitral valve leaflet was thickened with restricted motion and the sub-valvular apparatus were shortened and tethered. She had an estimated fair ejection fraction of 47% and moderate pulmonary arterial hypertension (RVSP 57.7 mmHg).

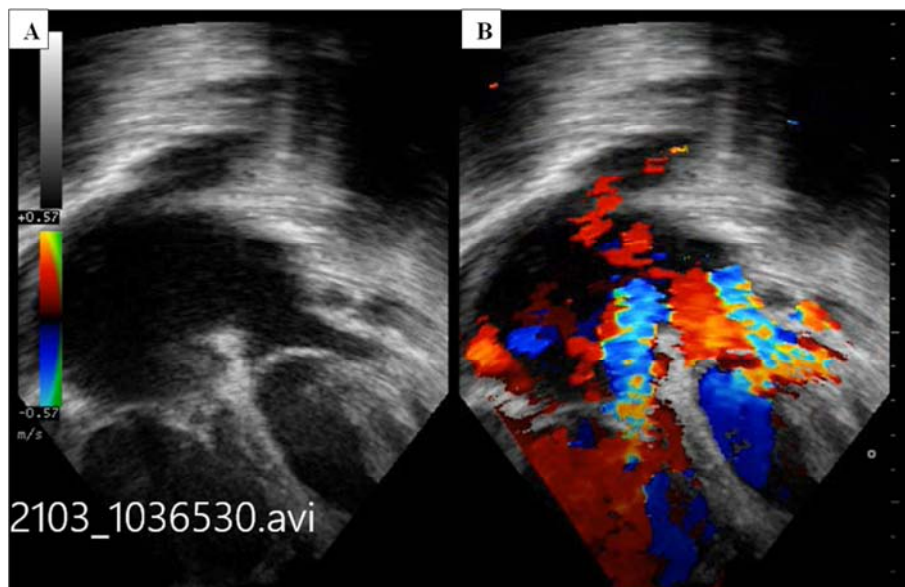


Figure 2. (A) 2-dimensional Echocardiography, apical 4 chamber view showing OS ASD, enlarge right heart chambers (B) Colour mapping demonstrating shunt across, MR and TR jets.

A diagnosis of a large ostium secundum ASD with left-to-right shunt, Rheumatic mitral disease with severe mitral regurgitation and moderate pericardial effusion was made and she was counseled for surgery.

Medical therapy with furosemide, hydrochlorothiazide and enalapril was instituted whilst waiting for surgery. During the waiting period she had an episode of congestive cardiac failure which was successfully managed medically.

She had open heart surgery 18 months after the initial presentation with the delay due to financial constraint.

Intra-operative findings were, 150 mL of serous pericardial fluid, cardiomegaly, mean pulmonary artery pressure of 27 mmHg, 45 mm wide ostium secundum ASD, prolapsed anterior mitral valve leaflet, fibrosed and thickened posterior mitral valve leaflet with calcification on the postero-medial commissure as well as shortened and fused chordae.

The anterior mitral valve leaflet was excised and a size 25 ATS mechanical valve was anchored into the mitral position while the ASD was closed with glutaraldehyde treated autologous pericardial patch,

Post-operative period was unremarkable and she was discharged home on post-operative day 9 with an INR of 2.7 on warfarin 7.5 mg daily. The pulmonary arterial pressure (RVSP 18.0 mmHg) and the Left ventricular ejection fraction (57%) had normalized one month thereafter.

3. Discussion

Atrial septal defect can co-exist with mitral regurgitation and the aetiology of the mitral regurgitation could be congenital or acquired. Congenital lesions of the mitral valve, as seen in partial atrioventricular septal defects (AVSD) is frequently a cleft in the mitral valve leaflet and other congenital abnormalities of the mitral valve resulting in insufficiency have also been described [3].

Ostium secundum ASD with acquired mitral regurgitation (MR) has also been described in literature, with various aetiopathogenesis [4-6]. Furuta and colleagues [6], proposed a specific pathophysiology called the ASD-MR complex, which is similar to the aortic regurgitation-ventricular septal defect (VSD-AR) complex. They proposed that abnormal left ventricular motion secondary to right ventricular volume overload leads to friction between the mitral valve leaflets, resulting in fibrous thickening on the medial aspect of the leaflet and consequently an incompetent mitral valve. Whatever the aetiology, overtime this combination leads to right ventricular volume overload, pulmonary hypertension and right ventricular dysfunction. This (right ventricular dysfunction) was becoming evident in our patient with elevated JVP, moderate tricuspid regurgitation and hepatomegaly.

Rheumatic involvement of the mitral valve leading to mitral stenosis (MS) in the presence of an ASD was first described by Lutembacher [7], hence the name Lutembacher syndrome. Some authors have argued that, mixed or insufficient mitral valve pathology, resulting from rheumatic heart disease and co-existing with an ASD should also be termed Lutembacher syndrome. However, the term is currently restricted to describe any combination of ASD and mitral stenosis [8].

Our patient was a 12 year old female with an OS ASD and rheumatic mitral regurgitation. This is in keeping with the female preponderance of this rare association as described in literature [1, 9, 10]. This female preponderance can be explained by the increased prevalence of ostium secundum atrial septal defects and rheumatic heart disease in females [9]. Some authors have also postulated that the atrial septal defects

seen in this association could be acquired from the hemodynamic effects of a significant mitral valve stenosis or regurgitation [10]. They argued that a back flow of blood into the left atrium leads to widening of a patent foramen ovale and consequent left to right shunt at the atrial level. This is unlikely to be the case in our patient considering the size and configuration of the ASD.

ASD on its own is largely asymptomatic especially in the age group of our patient, and the occurrence of symptoms in isolated ASD is dependent on the size of the defect and right ventricular compliance.

Hence the symptoms and the presence of pulmonary hypertension in this patient was most likely due to or worsened by the pathophysiological changes brought about by the degree and presence of rheumatic mitral regurgitation. The most disturbing symptom for our patient was palpitations and the fear was that she could have developed atrial fibrillation which would be a negative prognostic factor. However, she remained in sinus rhythm before, during and after surgery.

The echocardiographic and surgical assessment of the mitral valve showed fibrosis and thickening of posterior mitral valve leaflet with fused sub-valvular apparatus hence the mitral valve in this patient was not favourable for a valve repair. Also considering the progressive nature of rheumatic valve disease and consequent poor funding for re-intervention in our environment, a valve replacement was the best we could offer in this case. It is therefore instructive to report this case being the first in Nigeria to be so diagnosed and also surgically managed within the country.

4. Conclusion

Rheumatic mitral valve disease coexisting with congenital heart disease, in this case an Ostium secundum ASD though rare, presents a distinct pathophysiological mechanism which is determined by the size of the ASD, the right ventricular compliance and the degree of rheumatic mitral regurgitation. It should be recognized, diagnosed and treated early before disease modifying and life threatening complications sets in. As rheumatic heart disease remains a problem in developing countries such as ours, efforts should be geared towards its prevention, and the procedure offered for valvular lesions requiring surgery should be individualized.

References

- [1] Nasreen A, Sunil KA. Congenital heart disease (Atrial septal defect) with Rheumatic heart disease (Mitral Regurgitation) - A rare association. *JMSCR* 2017; 5 (7): 25003 - 5.
- [2] Waikittipong S. Mitral regurgitation associated with Secundum Atrial Septal Defect. *Thai J Surgery* 2010 Oct. 1; 31 (4): 120-4.
- [3] Mavroudis C, Backer CL. *Pediatric cardiac surgery*. 4th ed. Wiley-Blackwell, 2013: pg. 297.
- [4] Ballester M, Presbitero P, Foale R. Prolapse of the mitral valve in secundum atrial septal defect: A functional mechanism. *Eur Heart J* 1983; 7: 472-7.

- [5] Davies MJ. Mitral valve in Secundum atrial septal defects. *Br Heart J* 1981; 46: 126-8.
- [6] Furuta S, Wanibuchi Y, Ino T, Aoki K. Aetiology of mitral regurgitation in secundum atrial septal defect. *Jap Circulation J* 1982; 46: 346-51.
- [7] Lutembacher R. De la stenose mitrale avec communication interauriculaire. *Arch Mal Coeur* 1916; 9: 237-60.
- [8] Jain VV, Gupta OP, Jain J. A rare case of situs inversus with dextrocardia, Lutembacher syndrome and pericardial effusion. *Heart Views* 2011; 12: 107-11.
- [9] Barman B, Kapoor M, Lynrah KG, Issar NK, Nath D. Lutembacher's syndrome: A rare cause of right heart failure. *J Cardiovasc Dis Res* 2016; 7: 52-5.
- [10] Perloff JK, Marelli AJ. eds. The Clinical recognition of Congenital Heart Disease. 4th ed. Philadelphia: WB Saunders, 1994: 323-8.