

Case Report

Bleeding Complications in Organs Outside the Heart After Open Heart Surgery

Ihsanul Amal*, Heroe Soebroto

Department of Thoracic & Cardiovascular Surgery, Faculty of Medicine Airlangga University, Soetomo General Hospital, Surabaya, Indonesia

Email address:

dr.ihsanulamal@gmail.com (I. Amal)

*Corresponding author

To cite this article:

Ihsanul Amal, Heroe Soebroto. Bleeding Complications in Organs Outside the Heart After Open Heart Surgery. *International Journal of Cardiovascular and Thoracic Surgery*. Vol. 2, No. 4, 2016, pp. 22-25. doi: 10.11648/j.ijcts.20160204.12

Received: September 4, 2016; **Accepted:** October 8, 2016; **Published:** October 17, 2016

Abstract: Bleeding complications after open heart surgery are not unusual. However, bleeding complications that occur in other organs, such as brain and gastrointestinal tract, are rare. It is associated with significant morbidity and mortality after open heart surgery. These case series reported two patients who experienced complications after open heart surgery in the form of massive intracerebral hemorrhage and massive gastrointestinal tract bleeding. The similarity in both cases is prolonged cardiopulmonary bypass time.

Keywords: Open Heart Surgery, Cardiopulmonary Bypass, Anticoagulant, Bleeding Complications

1. Introduction

Open heart surgery for a wide variety of heart defects correction procedure is possible by the use of heart - lung machine or cardiopulmonary bypass (CPB). With advances in surgical techniques and extracorporeal oxygenation, mortality after open heart surgery is low. [1-3] However, bleeding still be a complication that accompanies. Bleeding complications may occur in up to 12% of patients after open heart surgery. [4] Bleeding in organs outside the heart may occur as a complication after open heart surgery. Bleeding locations reported in the literature can occur in the intracranial and intra-abdominal organs, either solid or hollow organ. [5-7] Bleeding complications after open heart surgery in general can be influenced by the preoperative, intraoperative, and postoperative risk factors. [8]

2. Case Description

2.1. Case 1

A 13 year-old male, weight 38 kg and height 155 cm, with double outlet right ventricle (DORV), sub-aortic ventricular septal defect (VSD) and major aortopulmonary collateral

arteries (MAPCAs) was consulted by pediatric cardiologist because of desaturation post MAPCAs coiling. Patient has been experiencing a bluish discoloration of lip and nails since 1 year-old. There was no history of head trauma and other neurological symptoms. From physical examination, there was cyanosis and clubbing fingers. Early oxygen saturation was 77%, after coiling was done, oxygen saturation dropped into 60%.

It was decided to do a total correction immediately. Hematological and biochemical parameters of preoperative are normal (platelet counts 231,000 g/dL). There was no history of previous use of anticoagulant drugs. Patient underwent total correction procedure using CPB. Anticoagulation for CPB was achieved by administration of heparin. The maximum value of activated clotting time (ACT) intraoperative was 702 seconds. Mean arterial pressure (MAP) during the procedure ranged between 45-80 mmHg. Blood gas analysis during on pump within normal limits. Total correction procedure lasted for 96 minutes. Transesophageal echocardiography evaluation revealed that there was significant residual VSD 4 mm in size, so the surgeon decided to put aortic cross clamp back to do the residual VSD repair. Second aortic cross clamp time lasted for 120 minutes. Total CPB time was 385 minutes. The patient was successfully weaned from CPB without any disturbances.

Protamine was given according to heparin dose to neutralize residual heparin after CPB.

Postoperative hemodynamic conditions were relatively stable without support. The next day, the patient can be weaned from the ventilator and then extubated. Nevertheless, the patient experienced decreased of consciousness and right hemiparesis (grade 2/5). Neurologic examination showed unequal pupils that reacts sluggishly to light. Glasgow Coma Score (GCS) was E-3, V-3, and M-5. Head CT scan revealed an intracerebral hemorrhage (ICH) on left frontotemporal as much as 68,3 ml with midline shift 0,7 cm and brain edema (Figure 1). Coagulation profile showed a prolongation of partial thromboplastin time (PTT) 36.8 / 24.8 seconds and platelet count decreased to 41,000 g/dL. Consultation to neurosurgeon was done immediately and then it was decided an emergency craniotomy to evacuate ICH after transfusion of 1 unit thrombocyte concentrate.

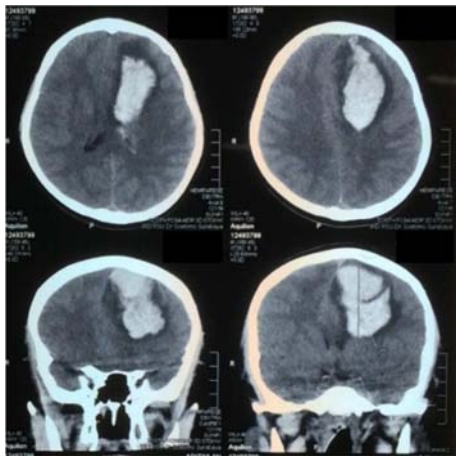


Figure 1. Preoperative Head CT Scan.

After emergency craniotomy, the patient regained his consciousness with GCS E-4, V-4, and M-5. The evaluation of head CT scan revealed a cerebral edema without midline shift (Figure 2). Patient transferred from the ICU to the intermediate care room on the 3rd day and discharged after 10 days later with improved right hemiparesis (grade 3/5).

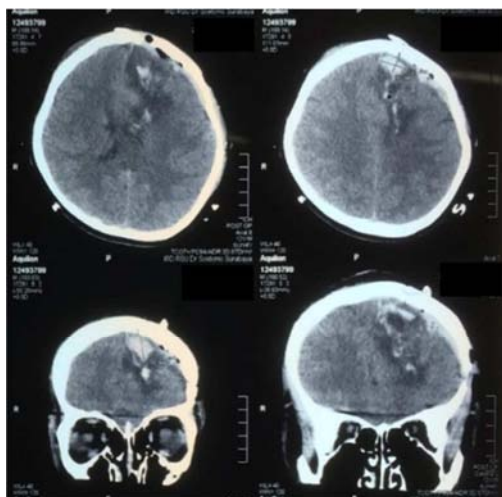


Figure 2. Postoperative Head CT Scan.

2.2. Case 2

A 50 year-old female, weight 49 kg and height 158 cm, with severe mitral stenosis (MS), moderate mitral regurgitation (MR), moderate aortic stenosis (AS), mild aortic regurgitation (AR) and moderate tricuspid regurgitation (TR) caused by rheumatic heart disease was planned to undergo double valve replacement (DVR) procedure. Clinically, patient presented with dyspnea on exertion and palpitation since the last 2 years. There was no history of orthopnea, paroxysmal nocturnal dyspnea, pedal edema, infective endocarditis, traumatic injury to head, or any neurological symptom. From the physical examination, we found an irregular pulse 110-120 x/min with a blood pressure of 130/70 mmHg. Atrial fibrillation was shown on electrocardiogram. The patient had been receiving warfarin 2 mg/day continuously and discontinued 1 week before surgery. Preoperative hematological and biochemical parameters are normal (platelet count = 212.000 g/dl, INR = 1.08).

The patient underwent the DVR procedure (31 mm mitral and 20 mm aortic mechanical valve) and tricuspid valve repair (TVr) De Vega procedure using CPB. Anticoagulation for CPB was achieved by administration of heparin. The maximum value of ACT intraoperative was 1096 seconds. MAP during the procedure ranged between 40-57 mmHg. During surgery, the prosthetic mitral valve had some mechanical issues that the surgeon had to replace it with another one. Aortic cross clamp time lasted for 253 minutes. Total CPB time was 313 minutes. Blood gas analysis obtained during surgery showed a metabolic acidosis. The patient was successfully weaned from CPB with the rhythm of atrial fibrillation. Protamine was given according to heparin dose to neutralize residual heparin after CPB.

After surgery, the patient was transferred to ICU in hypotensive condition (85/42 mmHg, MAP 60) with support of norepinephrine 20 µg/min, dobutamine 400 µg/min, and milrinone 25 µg/min. After 4 days, the hemodynamic and respiratory parameters were stable so the patient can be weaned from the ventilator and then extubated. Warfarin was given since the first day after surgery at a dose of 4 mg/day. INR evaluation on day 4th was 3.83 so the dose was lowered to 2 mg per day. However, on day 11th, the patient developed melena, fever, and anemia (Hb = 9.3 g/dl; INR = 2.25; platelet count = 213,000 g/dl) so that warfarin therapy was stopped temporarily.

The patient's condition failed to improve significantly until the day 17th, she suffered rectal bleeding with unstable hemodynamic condition. Consultation to digestive surgeon was done and then it was decided to do proctoscopy soon after hemodynamically stable to locate the source of bleeding. Proctoscopy showed that the rectum filled with clot, but the source of bleeding was not clearly visible, so it was decided to place rectal tampons and planned to do mesenteric arteriography. Extravasation of contrast arteriography was not obtained from the branches of the superior mesenteric artery, inferior mesenteric artery, coeliac trunk and other branches of abdominal aorta. On the 20th day, rectal bleeding occurred

profusely, so the surgeon decided to do a colonoscopy with a double set up laparotomy. Colonoscopy showed an active bleeding from internal hemorrhoid artery and the colon was filled with blood (Figure 3).



Figure 3. Colonoscopic View of Blood Filled Colon.

Laparotomy then performed and blood was found in the bluish colon along the ascending colon to sigmoid. The surgeon decided to do extended right hemicolectomy and end-to-end anastomosis of the ileum to the descending colon (Figure 4 & 5).

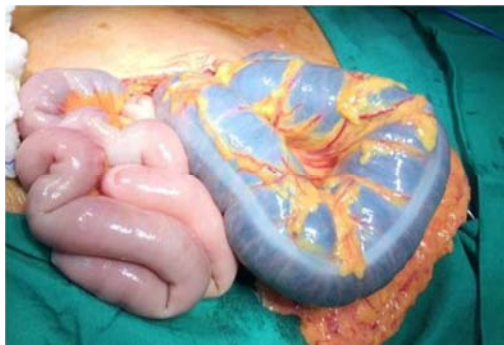

Figure 4. External View of Blood Filled Colon.

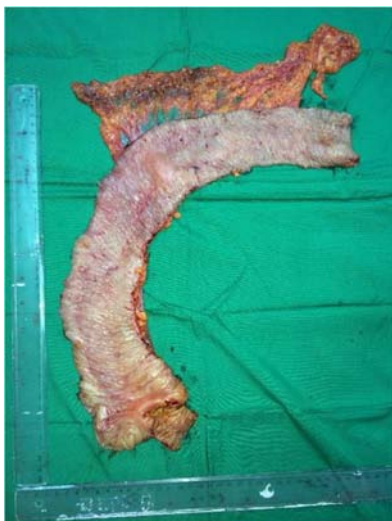

Figure 5. Excised Part of Colon.

Postoperative hemodynamic conditions were stable. However, rectal bleeding occurred again and the patient's condition worsened until the day 23rd after open heart surgery,

the patient died after the family refused to do any further action.

3. Discussion

Preoperative risk factors such as small body surface area (BSA) and small circulation volume, hepatic dysfunction, coagulation factors deficiency, von Willebrand disease, as well as a residual effect of warfarin and a history of thrombolytic therapy may increase the incidence of bleeding after open heart surgery. [8, 9] In both cases, there are preoperative risk factors such as BSA and circulation of small volume, as well as the history of the use of warfarin, while other risk factors was not known clearly. However, the patients with cyanotic congenital heart defect known to be prone to develop coagulation disorders include low platelet count, coagulation factor deficiency, fibrinolysis, and disseminated intravascular coagulation (DIC). [10]

The main intraoperative risk factor in the occurrence of bleeding after open heart surgery is the use of CPB. Bleeding risk would be higher if CPB time exceeding 120 minutes. [8] In both cases, the total CPB time was over 300 minutes. Total CPB time over 120 minutes known to be associated with a significant reduction of the number of platelets. [11] Thrombocytopenia that occurs will be more progressive along with prolonging of CPB time. Protamine administration also reduces the number of platelets up to 30%. [8] In the first case, the platelet count decreased dramatically from 231,000 g/dL preoperatively to 41,000 g/dL postoperatively. The decrease in platelet count may occur due to hemodilution by priming fluids other than blood, platelet adhesion to the surface of the extracorporeal circuit, platelet aggregation and activation and removal of damaged platelet by the reticulo-endothelial system. [11]

In the first case, there were complications such as bleeding of the left frontotemporal ICH as much as 68.3 mL with midline shift of 0.7 cm and cerebral edema. The main mechanism of ICH occurring after open heart surgery is trauma or cerebral volume changes due to fluid shifts during CPB time that causes tearing of dural veins. Vascular malformations of the brain and a history of previous seizures can also be a risk factor of the ICH. In pediatric patients, the softer and less myelinated brain structures is predispose to trauma. The smaller left atrium size can also cause poor drainage or return of vena cava blood flow, causing edema and rupture of the capillaries of the brain. [12]

In the second case, the bleeding complications happen as lower gastrointestinal tract bleeding. The mechanism underlying these complications is the splanchnic hypoperfusion due to hypovolemia, prolonged CPB time, and intraoperative administration of vasoconstrictor. [13] In addition, the CPB also can increase gastrointestinal permeability and the release of cytokines that produce mucosal damage and microcirculation problem. [14] Splanchnic hypoperfusion can also be caused by the prolonged mechanical ventilation. Prolonged mechanical ventilation with high PEEP can cause a decrease in cardiac

output, hypotension, and increased activity of the renin-angiotensin-aldosterone and catecholamines, causing splanchnic vasoconstriction and redistribution of blood flow. The imbalance between supply and oxygen demand causes ulceration and motility disorders. [14]

4. Conclusion

Bleeding in organs outside the heart may occur as a complication after open heart surgery. These complications can be influenced by various preoperative, intraoperative, and postoperative risk factors. By understanding these factors, bleeding complications in organs outside the heart after open heart surgery can be reduced and management of complications can be quickly done to prevent further morbidity and mortality.

References

- [1] Stark et al. Mortality rates after surgery for congenital heart defects in children and surgeons' performance. *The Lancet Public Health* 2000, Vol 355, no 9208, p1004-1007.
- [2] Edwards F, Peterson E, Coombs L, et al. Prediction of operative mortality after valve replacement surgery. *J Am Coll Cardiol*. 2001; 37(3): 885-892. doi:10.1016/S0735-1097(00)01202-X.
- [3] Keogh B, Kinsman R. Fifth national adult cardiac surgical database report 2003: improving outcomes for patients. Oxfordshire UK: Dendrite Clinical Systems; 2004.
- [4] Hall et al. Re-exploration for Hemorrhage Following Open Heart Surgery Differentiation on the Causes of Bleeding and the Impact on Patient Outcomes. *Ann Thorac Cardiovasc Surg* 2001; 7: 352-7.
- [5] Chrastina et al. Neurosurgical Treatment of Cerebrovascular Complications of Heart Surgeries and Interventions. *Turk Neurosurg* 2014, Vol: 24, No: 6, 897-905.
- [6] Schwartz et al. 2013. Chapter 14: Gastrointestinal Complications in Cardiothoracic Surgery: A Synopsis. In *Principles and Practice of Cardiothoracic Surgery*. InTech, pp 355-371.
- [7] Iriz E, Ereren E, Yuksel O, Kalaycioglu S. Free Intra-Abdominal Hemorrhage after Open-Heart Surgery, an Unusual Gastrointestinal Complication. *Tex Heart Inst J* 2006; 33: 523-5.
- [8] Ozolina et al. Excessive Bleeding After Cardiac Surgery in Adults: Reasons and Management. *Acta Chirurgia Latviensis*, 2009 (9). doi: 10.2478/v10163-010-0017-2.
- [9] Despotis G, Avidan M, Eby C. Prediction and management of bleeding in cardiac surgery. *J Throm Haemost* 2009; 7 (Suppl. 1): 111-7.
- [10] Ghasemi A, Horri M, Salahshour Y. Coagulation Abnormalities in Pediatric Patients with Congenital Heart Disease: A Literature Review. *International Journal of Pediatrics*, Vol. 2, N. 2-2, Serial No. 5, Apr 2014.
- [11] Tetley et al. Predictors of Post-Operative Bleeding and Blood Transfusion in Cardiac Surgery. *Ghana Medical Journal*, Vol.2, N. 43, Jun 2009.
- [12] Yuan SM, Guo JQ. Subsequent intracranial hemorrhage following open heart surgery. *Ann Coll Surg Hong Kong* 2001; 5: 66-73.
- [13] Zacharias et al. Predictor of gastrointestinal complications. *Tex Heart Inst J* 2000; 27: 93-9.
- [14] D'Ancona et al. Determinants of gastrointestinal complications in cardiac surgery. *Tex Heart Inst J* 2003; 30: 280-285.