



Acute Aortic Dissection at the Cardiology Clinic to the University National Hospital Hubert Koutoukou Maga of Cotonou (BENIN)

Kémal Bori Bata¹, Arnaud Sonou¹, Hugues Dohou², Donald Aïkpon^{1,*}, Mayeul Agbo¹, Carmel Abatti¹, Maurice Dangbegnon¹, Murielle Hounkponou¹, Xavier Fadonougbo¹, Phillipe Agbalika¹, Francis Soummonni¹, David Dossou¹, Léopold Houétondji Codjo¹

¹Cardiology Teaching and Research Unit and University Cardiology Clinic, National University Hospital Center Hubert Koutoukou Maga and Faculty of Health Sciences of Cotonou, Abomey Calavi, Benin

²Cardiology Teaching and Research Unit Cardiology Department, Borgou/Alibori Departmental University Hospital Center Faculty of Medicine, Parakou, Benin

Email address:

bbak@live.fr (Kémal Bori Bata), arnsonou@gmail.com (Arnaud Sonou), huguesdohou@gmail.com (Hugues Dohou),

aikpondonald@gmail.com (Donald Aïkpon)

*Corresponding author

To cite this article:

Kémal Bori Bata, Arnaud Sonou, Hugues Dohou, Donald Aïkpon, Mayeul Agbo et al. (2023). Acute Aortic Dissection at the Cardiology Clinic to the University National Hospital Hubert Koutoukou Maga of Cotonou (BENIN). *International Journal of Cardiovascular and Thoracic Surgery*, 9(6), 71-76. <https://doi.org/10.11648/j.ijcts.20230906.11>

Received: November 1, 2023; Accepted: November 20, 2023; Published: December 6, 2023

Abstract: *Introduction:* We aimed to describe epidemiological, diagnostic, therapeutic aspects of aortic dissection (AD) managed at the CNHU-HKM of Cotonou (Benin). *Methods:* It was a retrospective study from January 2018 to July 2023. All patients admitted for AD were enrolled. AD was classified as type A and type B according to Stanford. DA risk factors, socio-demographic characteristics and DA characteristics were studied. *Results:* Of the 2883 patients admitted during the study period, there were 17 cases of AD, representing a frequency of 0.6%. The mean age was 52 ± 9 years, and the sex ratio was 3.25. Uncontrolled hypertension was the predominant risk factor (88.3%). The main manifestations of AD were chest pain (100%) and aortic insufficiency (52.94%). Chest X-rays showed enlargement of the mediastinum in all patients. Echocardiography showed intimal flap in 62.5%. The aortic angiotomodensitometry identified 12 type A (70.59%) and 5 type B (29.41%) of AD. Surgical or endovascular treatment was performed in 6 (35.29%) patients. Lethality rate was 47.06%. *Conclusion:* Aortic dissection was frequent at the teaching clinic of cardiology of CNHU-HKM of Cotonou. Surgical or endovascular treatment wasn't often available, and mortality was high. Prevention of this condition must be the rule, and it requires adequate management of hypertension, which is the most common risk factor.

Keywords: Aortic Dissection, Arterial Hypertension, Cardiovascular Surgery, Benin

1. Introduction

Aortic dissection (AD) is a longitudinal cleavage in the media originating from an intimal breach and creating a true and a false channel [1]. The annual incidence is 6 cases per 100,000 [2]. Its hospital incidence was 0.24% in Senegal in 2010; 1.28% in Benin in 2017 [3, 4]. Without treatment, the disease often progresses to complications (extension, ischemia, aneurysm, rupture) [5]. Mortality remains high,

ranging from 30% in European series to 53%-83% in African series [3, 4, 6]. Surgery remains the treatment of choice for all aortic dissections. However, it remains inaccessible in many West African countries [3, 4, 6].

The aim of this study is to report on the epidemiological, diagnostic, therapeutic and evolutionary aspects of aortic dissection cases managed at the CNHU-HKM in Cotonou (Benin), the national reference center.

2. Methods

This is a retrospective study extending from January 2018 to July 2023 at the university cardiology clinic (CUC) of the CNHU-HKM in Benin. We included in this study all patients presenting with acute or chronic AD without prejudice to type, or etiology. Unconfirmed cases of AD were not included. The parameters studied were: socio-demographic characteristics (age, sex, profession); patient's background (cardiovascular risk factors, cardiovascular diseases, other comorbidities); characteristics of AD (type; clinical expression; etiology, treatment, complications).

In our study, we used the Stanford classification to define the type of aortic dissection [7]. Arterial hypertension was classified into 3 stages according to ESH 2023 recommendations [8].

Data were processed and analyzed using Epi-Info 7.2 software. Authorization was received from the Director General of CNHU-HKM, and data confidentiality was respected. The data collected were used only for the purposes of the study.

3. Results

During the study period, 2883 patients were admitted. Seventeen (17) patients (0.6%) had presented with aortic dissection.

3.1. General Characteristics and Risk Factors

The mean age was 52 ± 9 years, with extremes of 34 and 69 years. There were 13 men, for a sex ratio of 3.25.

The distribution of risk factors is shown in Table 1.

Table 1. Presentation of risk factors in patients with Aortic Dissection managed at the CNHU-HKM of Cotonou (Benin) from January 2018 to July 2023.

	Workforce	Percentage (%)
Caractéristiques générales		
Age (y)		
<40	2	11,7
40-49	4	23,5
≥50	11	64,7
Sex-ratio	3,2	
Profession		
Civil servants	03	17,6
Craftsmen	02	11,8
Shopkeepers	10	58,8
Other*	02	11,8
Atherosclerosis risk factors		
Hypertension	15	88,3
Dyslipidaemia	06	35,3
Obesity	07	41,1
Smoking	02	11,7
Diabete	04	23,5
Other risk factors for aortic dissection		
Aortic aneurysm	05	29,4
Chest trauma	02	11,7
Annulo-ectatic disease	01	5,9

Other: driver, contractor

3.2. Clinical and Paraclinical Presentation

Clinically, the main symptom was chest pain, which was observed in all patients. Mean systolic blood pressure (SBP) on admission was 165 ± 25 mmHg, with extremes ranging from 156 to 193mmHg. Mean diastolic blood pressure (DBP) was 99 ± 20 mmHg with extremes from 61 to 115mmHg. Hypertension was at least grade 2 in 66.27% of patients. Table 2 summarizes the clinical characteristics of these patients.

On the paraclinical level, left ventricular hypertrophy was the main abnormality observed on the electrocardiogram (47.05%).

Table 3 shows the electrocardiogram abnormalities found in our patients.

Table 2. Clinical characteristics of patients who presented with Aortic Dissection at the CNHU-HKM in Cotonou (Benin) from January 2018 to July 2023.

Clinical characteristics	Workforce	Percentage (%)
Symptoms		
Chest pains	17	100
Dyspnea	05	29,41
Hemoptysis	01	05,88
Syncope	01	05,88
Palpitations	01	05,88
Physical signs		
Hypertension		
Grade 1	5	33,33
Grade 2	4	26,27
Grade 3	6	40,00
Aortic insufficiency murmur	09	52,94
Anisotension	08	47,06
Anisophygma	08	47,06
Haemothorax	02	11,76

Table 3. The distribution of electrocardiographic characteristics found in patients who presented with Aortic Dissection at the CNHU-HKM of Cotonou (Benin) from January 2018 to July 2023.

Electrocardiographic features	Workforce	Percentage (%)
Left ventricular hypertrophy	08	47,05
Conduction disorders (complete BAV)	03	17,64
ST-segment elevation	02	11,76
Subepicardial ischemia	01	5,88
R-wave planning	01	5,88
No abnormalities	02	11,76

Chest X-rays were taken in all our patients, and revealed an enlarged mediastinum in all cases, and a double-contour image of the aortic arch in two. Hemothorax was also found in two of our patients. Figure 1 shows a radiograph of one of the two patients, with an enlarged mediastinum and a double-contour image of the aortic arch.

Echocardiographically, intimal flap was found in 10 patients (62.5%). Pericardial effusion was the major complication found on transthoracic echocardiography (40%).

Figure 2 shows the intimal flap on transthoracic echocardiography in one of our patients with type B aortic dissection.

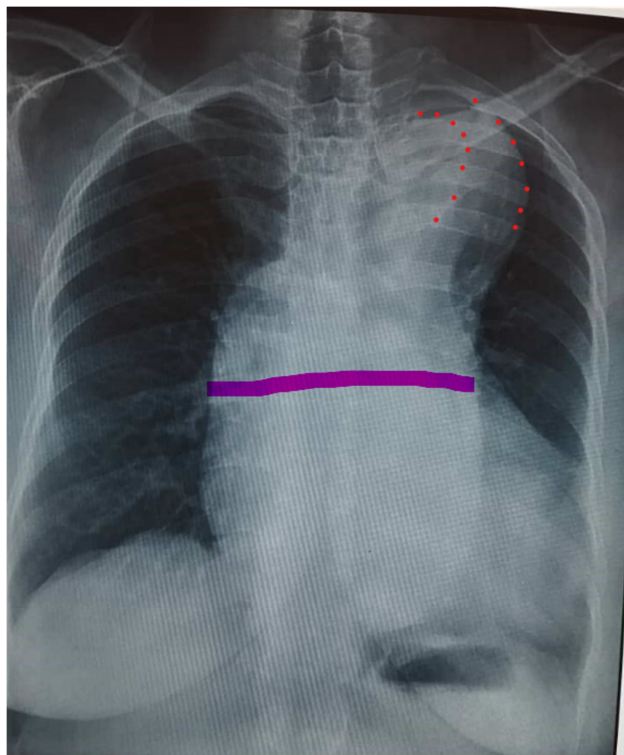


Figure 1. Chest x-rays of a patient with Stanford type A aortic dissection at the CNHU-HKM in Cotonou, Benin, showing enlargement of the mediastinum (solid line) and a double-contour image of the aortic arch (dotted line).

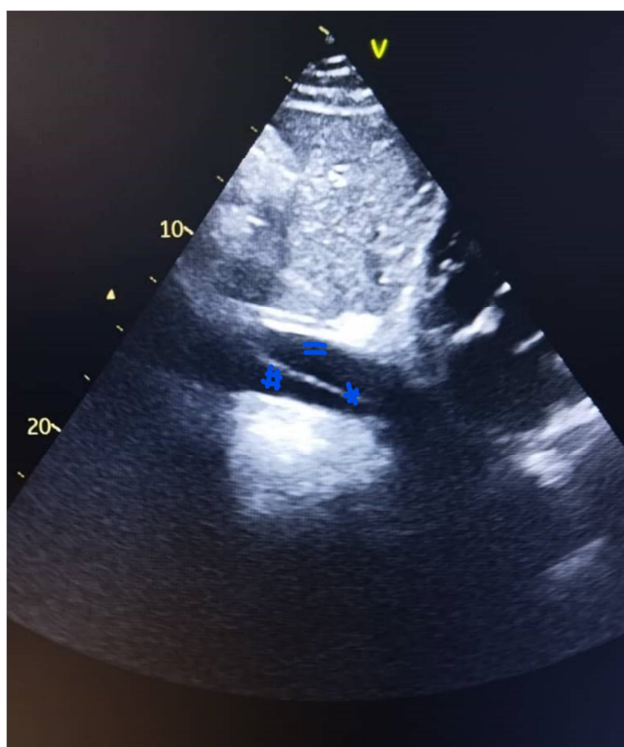


Figure 2. Two-dimensional transthoracic echocardiographic image in subcostal incidence showing the intimal flap (*) at the level of the abdominal aorta delimiting the true channel (#) from the false channel (=) in a patient with Type B Aortic Dissection managed at the CNHU-HKM of Cotonou between 2018 and 2023.

Thoracic angioscanner performed in the 17 patients found 12 cases (70.59%) of type A aortic dissection and 5 cases (29.41%) of type B aortic dissection.

Figure 3 shows a CT image of a type A aortic dissection extending into the abdominal aorta.

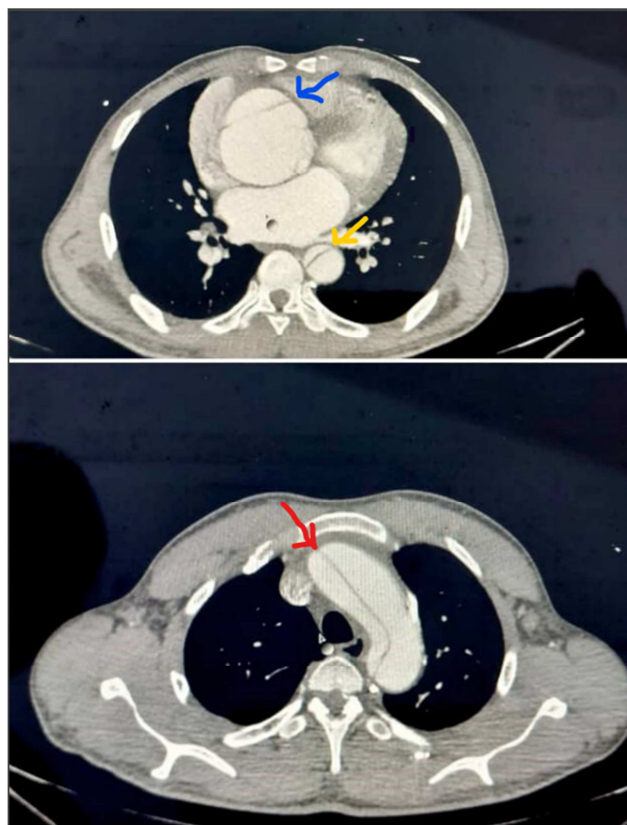


Figure 3. CT image showing type A aortic dissection extending to the abdominal aorta in one of the patients in our study at the CNHU-HKM in Cotonou between 2018 and 2023 (Blue: intimal flap at the level of the ascending thoracic aorta on this CT section passing through T7; yellow: intimal flap at the level of the descending thoracic aorta on this scan section passing through T7; red: intimal flap at the level of the aortic arch on this scan section passing through T4).

3.3. Management and Short-Term Complications

At the end of the evaluation, the immediate complications found were: extension to the iliac arteries (6 patients); extension to the mesenteric arteries (3 patients), renal arteries (2 patients), cerebral arteries (3 patients); coronary arteries (2 patients) and pericardial effusion (6 patients).

All patients in our study were treated with antihypertensive drugs to achieve a blood pressure of less than 120/70 mmHg, and anxiolytics. Beta blockers were used in all patients to achieve a heart rate below 60 bpm. In some cases, analgesics and laxatives were used.

Surgically, 6 patients (35.29%) underwent surgery. Of these, 5 underwent open surgery, and 1 patient underwent endovascular surgery, such as placement of a stent graft in the thoracic aorta, indicated for type B DA.

Waiting times for surgery ranged from 5 days to 6 months. The different types of open surgery performed are shown in Table 4.

Table 4. The different types of open surgery performed on aortic dissection patients at the CNHU-HKM of Cotonou from 2018 to 2023.

Type	Workforce	Percentage (%)
Mechanical Bentall + anterior hemi cruciate replacement	1	20
Modified David + aortic endoprosthesis	1	20
Replacement of ascending aorta and aortic arch with thoraflex hybrid prosthesis	1	20
Replacement of ascending aorta and aortic arch, reimplantation of brachiocephalic arterial trunk and carotid artery, venous bypass on right coronary artery	1	20
Mechanical valve replacement in aortic position + and placement of a prosthetic tube over the coronary artery	1	20
TOTAL	5	100,00

Immediate postoperative complications are shown in Table 5.

Table 5. Immediate postoperative complications found in patients suffering from aortic dissection at the CNHU-HKM of Cotonou and operated on from 2018 to 2023.

Immediate postoperative complications	Workforce
None	2
Ischemic stroke	1
Onset of left ventricular failure	1
Paroxysmal rhythm disorders	1
Complete BAV, one paroxysmal and one permanent, with PM implantation	2
Hypoxemic respiratory failure	1
Sepsis	1
Cardiogenic and vasoplegic shock	1

Eight deaths were recorded, representing a case-fatality rate of 47.06%. The distribution of these deaths is shown in Table 6.

Table 6. Surgical distribution of aortic dissection patients at CNHU-HKM Cotonou from 2018 to 2023.

Type of aortic dissection	Operated		Not operated	
	Dead	Living	Dead	Living
A	0	5	7	0
B	1	0	0	4
Total	1	5	7	4

Among the cases of type A DA operated on, one patient was reoperated on after seven years. This patient had initially undergone modified David surgery with thoracic stenting. He developed a progressively worsening false anastomotic aneurysm, which required successful placement of a covered stent graft in the ascending aorta.

As for the patients suffering from type B DA, the only one who benefited from endovascular treatment died after 6 months from a recurrence of type A DA due to a hypertensive flare-up caused by non-compliance with treatment. He could not be treated due to financial constraints.

4. Discussion

This work has enabled us to describe the epidemiological, clinical therapeutic and evolutionary aspects of AD at CNHU-HKM between 2018 and 2023. The data we have reported should serve as a basis for further work on this medico-surgical emergency of aortic dissection [1].

The hospital frequency of AD in our study was 0.6%. This is higher than that found in 2010 by Ndiaye et al (0.24%) over a 22-year period in Dakar [3]. It is lower than that reported by ADJAGBA et al in Cotonou in 2017 (1.28%) [4]. All this is proof that aortic dissection is increasingly found in Africa, thanks to the acquisition of high-performance diagnostic tools.

The mean age of patients in our study was 52 years (32-69 years); this is in line with the literature and is explained by the altered resistance of the aortic wall with advancing age, most often combined with atherosclerosis [9].

In our series, uncontrolled hypertension (88.3%) was the predominant risk factor. Indeed, uncontrolled hypertension is the main factor triggering AD in 40-90% of cases [1, 6]. Forty (40%) of our patients had grade III hypertension. Howard et al [10], in a study carried out in the USA, reported 47% grade III hypertension in patients presenting with AD in their series.

Other risk factors for AD that we observed were annulo-ectatic disease, thoracic trauma and pre-existing aortic aneurysm. Other antecedents such as smoking, aortic bicuspidism, Marfan syndrome, previous aortic surgery and pregnancy have been reported by other authors [4, 11].

No incidental findings were made in our study. The clinical signs found were the same as those described in the literature. Indeed, chest pain was the main symptom presented by all our patients. In other studies, it was found in an average of 90% of cases [4, 6, 12]. Few series have described DA without chest pain, discovered incidentally, which can make diagnosis difficult and delayed [13]. Aortic insufficiency was present in 52.94% of patients in our series. In general, it represents the most frequent complication (40-70%) of Stanford type A aortic dissection [14]. Anisophymia was noted in 47% of our patients. It was present

in 35% in a study carried out by Evangelista et al [15] in Spain in 2021. Anisophygmia is therefore not always present in this pathology.

On ECG, in our study, almost half the patients (47%) had left ventricular hypertrophy. This shows that the majority of hypertensive patients already had myocardial damage caused by hypertension. In 15% of cases, the ECG showed repolarization abnormalities unrelated to left ventricular hypertrophy. These abnormalities are probably linked to the extension of the aortic dissection to the coronary arteries in these patients. The ECG can therefore sometimes be abnormal in terms of repolarization and misleading [4].

Chest X-rays were taken in all our patients. They revealed enlargement of the mediastinum in all cases and aortic contour anomalies in two patients. These two radiological signs have a sensitivity of 64% and 71% respectively [16]. In any case, a normal radiograph cannot exclude aortic dissection. One patient had a hemothorax, one of the potentially serious complications of aortic dissection [2]. These radiological abnormalities corroborate those found in the literature [16].

In our study, cardiac echodoppler contributed to the diagnosis. It identified intimal flap (62%), aortic insufficiency (53%) and hemopericardium (40%). Other complications, such as segmental kinetic disorders due to extension to the coronary arteries, were not found in our series. In Vázquez's series, cardiac echodoppler was diagnostic in 75% of cases, and no disturbance of segmental kinetics was found [17]. This proves the importance of this diagnostic tool in this pathology.

Thoracic angioscan confirmed the diagnosis in all cases. Its sensitivity and specificity are 83% and 90% respectively [5]. With the new generation of helical multibeam CT scanners, sensitivity approaches 100%, while specificity ranges between 98 and 99% [16].

All our patients benefited from medical treatment. Whatever the type of AD, analgesic treatment and blood pressure control are recommended [6]. Apart from medical treatment, emergency surgery is the rule for type A DA, sometimes combined with endovascular treatment [18]. The natural history of type A aortic dissection is catastrophic in the absence of surgical treatment: mortality is close to 20% in the first 24 hours, with a risk progression of 1 to 2% per hour from the first symptom, 30% in the first 48 hours and 50% in the first week [19]. Unfortunately, surgery was only available for 5 patients (35.29%), and at a late stage. This explains why, in our series, all patients with type A AD who were unable to benefit from surgery died as a result of progressive complications.

Of the 12 patients with type A aortic dissection, 5 underwent successful surgery. Two of these were treated locally, thanks to the advent of cardiac surgery in our country. The remaining patients were operated on after medical evacuation to France.

Despite advances in technology, especially in developed countries, acute aortic dissection remains a cardiovascular emergency with a dreadful prognosis; in-hospital mortality is between 20% and 30% in most series [17]. The case-fatality rate for AD in our series was 47%. This rate is similar to that

found by MB Ndiaye et al in Dakar in 2010 (52%); but lower than that found by ADJAGBA et al in Cotonou in 2017 (83%). This difference can be explained by the fact that in our series, 35% of patients were able to benefit from a surgical procedure, as opposed to 16% in the series by ADJAGBA et al in 2017. Access to surgery is therefore a key factor in strategies to reduce type A AD-related deaths. The efforts of the political-administrative authorities in setting up cardiac surgery in Benin must be encouraged and pursued.

5. Conclusion

Aortic dissection is a serious disease, with a high mortality rate. Uncontrolled hypertension is the major cause of AD in 80% of cases. Surgery remains the treatment of choice, but is not always accessible. Surgical treatment does not exclude etiological treatment. The most urgent need, therefore, is to prevent this condition through proper management of hypertension.

Conflicts of Interest

The authors declare no conflicts of interest.

References

- [1] Fournot L, Boulate D, Kirsch M, Leprince P. Surgical management of acute aortic dissection. *Réanimation*, 2013, vol. 22, p. 600-609. URL: <https://revuemir.srlf.org/index.php/mir/article/view/630>
- [2] Howard DP, Sideso E, Handa A, Rothwell PM. Incidence, risk factors, outcome and projected future burden of acute aortic dissection. *Ann Cardiothorac Surg* 2014; 3: 278-84. doi: 10.3978/j.issn.2225-319X.2014.05.14. PMID: 24967167; PMCID: PMC4052413.
- [3] Diao M, Ndiaye MB, Kane AD, Mbaye A, Doucouré I, Sarr M, et al. Diagnostic, therapeutic and evolutionary aspects of dissection in Dakar. Retrospective study of 19 cases. *Médecine d'Afrique noire*. 2010 Feb; 57 (8/9): 419-4. <https://www.researchgate.net/publication/280446288>
- [4] Adjagba MP, Bognon R, Sonou A, Hounkponou M, Djoh I, Assani MS, et al. Diagnostic and prognostic particularities of aortic dissection at the cnhu-hkm of Cotonou, Benin: A propos de 6 cas en 2017. *Eur Sci ESJ* 2018; 14 (18): 206. Available from: <https://eujournal.org/index.php/esj/article/view/10967>
- [5] Baliyan V, Parakh A, Prabhakar AM, Hedgire S. Acute aortic syndromes and aortic emergencies. *Cardiovasc Diagn Ther*. 2018 April; 8 (Suppl 1): S82-S96. doi: 10.21037/cdt.2018.03.02.
- [6] Erbel R, Aboyans V, Boileau C, Bossone E, Bartolomeo RD, Eggebrecht H, et al. 2014 ESC Guidelines on the diagnosis and treatment of aortic diseases: Document covering acute and chronic aortic diseases of the thoracic and abdominal aorta of the adult. The Task Force for the Diagnosis and Treatment of Aortic Diseases of the European Society of Cardiology (ESC). *Eur Heart J*. 2014 Nov 1; 35 (41): 2873-926. doi: 10.1093/eurheartj/ehu281.

- [7] Debakey ME, Henly WS, Cooley DA, Morris GC, Crawford ES, Beall AC. Surgical management of dissecting aneurysms of the aorta. *J Thorac Cardiovasc Surg.* 1965; 49: 130- 49. [https://doi.org/10.1016/S0022-5223\(19\)33323-9](https://doi.org/10.1016/S0022-5223(19)33323-9)
- [8] Mancia G, Kreutz R, Brunström M, Burnier M, Grassi G, Januszewicz A, et al. 2023 ESH Guidelines for the management of arterial hypertension The Task Force for the management of arterial hypertension of the European Society of Hypertension Endorsed by the International Society of Hypertension (ISH) and the European Renal Association (ERA). *J Hypertens.* 2023 Jun 21. DOI: 10.1097/HJH.0000000000003480.
- [9] Daily PO, Trueblood HW, Stinson EB, Wuerflein RD, Shumway NE. Management of acute aortic dissections. *Ann Thorac Surg.* 1970; 10: 237-47. [https://doi.org/10.1016/S0003-4975\(10\)65594-4](https://doi.org/10.1016/S0003-4975(10)65594-4)
- [10] Howard D, Banerjee A, Fairhead JF, Perkins J, Silver LE, Rothwell PM et al. Population-Based Study of Incidence and Outcome of Acute Aortic Dissection and Premorbid Risk Factor Control: 10-year results from the Oxford Vascular Study. *Circulation AHA Journal.* 2013 May 21.127 (20): 2031-7. <https://doi.org/10.1161/CIRCULATIONAHA.112.000483>
- [11] Dib B, Seppelt PC, Arif R, Weymann A, Veres G, Schmack B et al. Extensive aortic surgery in acute aortic dissection type A on outcome-insights from 25 years single center experience. *J Cardiothorac surg.* 2019 Nov 6. 14 (1): 187. <https://doi.org/10.1186/s13019-019-1007-7>
- [12] Wang W, Duan W, Xue Y, Wang L, Liu J, Yu S et al. Clinical features of acute aortic dissection from the registry of aortic dissection in China. *The Journal of Thoracic and Cardiovascular Surgery.* 2014 December. 148 (6): 2997. <https://doi.org/10.1016/j.jtcvs.2014.07.068>
- [13] Gebril A, Nawaz A, Ashour S, Nasr MK, Eelbelihy OE. Accidentally discovered type B silent aortic dissection in a COVID-19 positive patient. *Cureus.* 2023 Jul 4; 15 (7): e41373. DOI: 10.7759/cureus.41373.
- [14] Golledge J, Eagle KA. Acute aortic dissection. *Lancet.* 2008 Jul 5; 372 (9632): 55-66. [https://doi.org/10.1016/s0140-6736\(08\)60994-0](https://doi.org/10.1016/s0140-6736(08)60994-0)
- [15] Evangelista A, Barrabés J, Lidon RM, Rodriguez-Lecoq R. Changes in the diagnosis and management of acute aortic syndrome and associated mortality over the past 20 years. *REVISTA ESPANOLA DE CARDIOLOGIA.* 2021; 74: 257-262. <https://doi.org/10.1016/j.rec.2020.02.015>
- [16] Hiratzka LF, Bakris GL, Beckman JA, Bersin RM, Carr VF, Casey DE et al. 2010 ACCF/AHA/AATS/ACR/ASA/SCA/SCAI/SIR/STS/SVM guidelines for the diagnosis and management of patients with thoracic aortic disease: un rapport de l'American College of Cardiology Foundation/American Heart Association Task Force on Practice Guidelines, de l'American Association for Thoracic Surgery, de l'American College of Radiology, de l'American Stroke Association, de la Society for Cardiovascular Anesthesiologists, de la Society for Cardiovascular Angiography and Interventions, de la Society for Interventional Radiology, de la Society of Thoracic Surgeons et de la Society for Vascular Medicine. *Circulation.* 2010 Apr 6; 121 (13): e266-369. <https://doi.org/10.1161/cir.0b013e3181d4739e>.
- [17] Vázquez Muñoz CA, Delgado Osorio H. Acute dissection of the thoracic aorta: experience at the Puerto Rico Medical Center (1991 through 1995). *Bol Asoc Med P R.* 1997 Oct-Dec; 89 (10-12): 161-6. <https://pubmed.ncbi.nlm.nih.gov/9580383/>
- [18] Rousseau H, Chabbert V, Marcheix B, El Hassar O, Cron C, Lopez S. Acute aortic syndromes. *STV.* 2009; 21 (3): 112-25. <https://pubmed.ncbi.nlm.nih.gov/24796906/>
- [19] Nienaber CA, Clough RE. Management of acute aortic dissection. *Lancet.* 2015 Feb 28; 385 (9970): 800-11. [https://doi.org/10.1016/s0140-6736\(14\)61005-9](https://doi.org/10.1016/s0140-6736(14)61005-9)